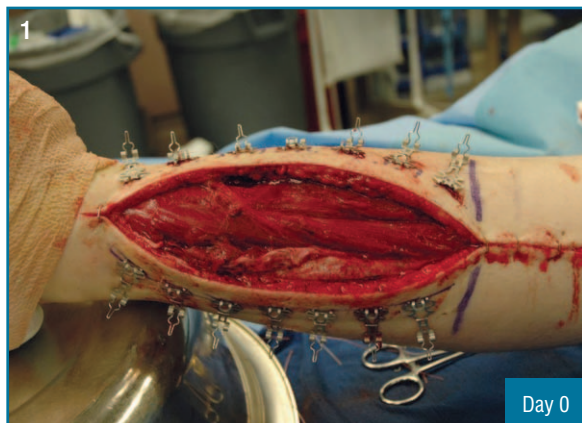


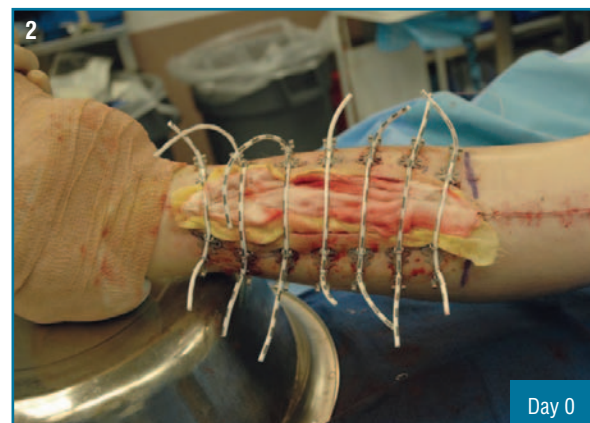
## Fasciotomies

### History

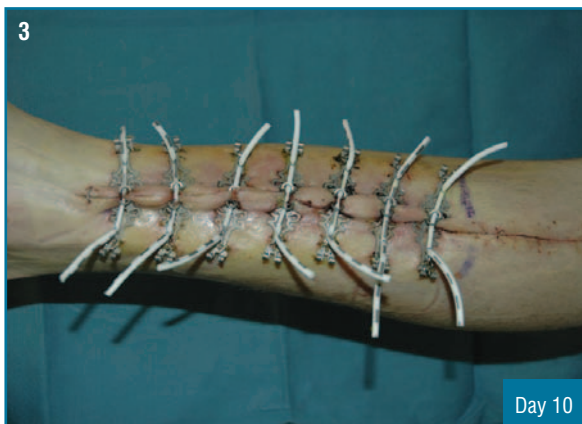
A 20 year old man involved in a motor vehicle accident, suffered an extremity compartment syndrome which required a bilateral fasciotomy on the left leg. Six days later, the surgical skin closure system was applied on the lateral incision while the surgeon closed the medial side primarily. The patient was returned to the operating room ten days later where the system was removed and the lateral side was primarily closed.



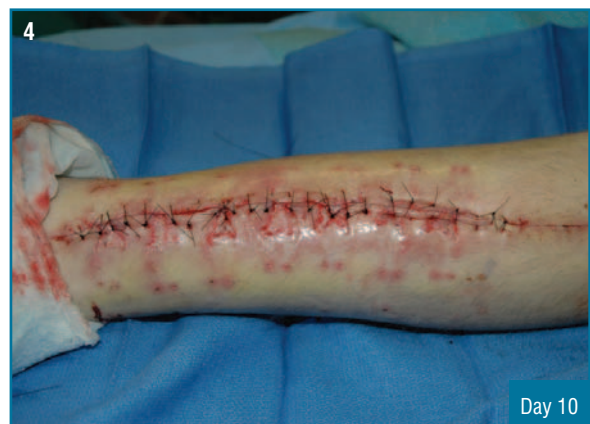Measuring 30 cm x 7.5 cm, six days post bilateral fasciotomy



Surgical Skin Closure system as installed



Ready for closure ten days after installation of Surgical Skin Closure system.



Delayed primary closure